

Original Article

Effectiveness of intraperitoneal or intrapleural administration of triamcinolone acetonide for the control of malignant ascites and pleural effusion (Kansai Clinical Oncology Group-G1102 study)

ABSTRACT

Objectives: We conducted a retrospective multi-institutional study to evaluate the efficacy and toxicity of intraperitoneal or intrapleural triamcinolone acetonide (TA), a slowly metabolized corticosteroid administration for the management of malignant ascites or pleural effusion.

Materials and Methods: The medical records of patients with gynecologic cancer who were treated with paracentesis or thoracocentesis followed by administration of 400 mg of TA between 2005 and 2014 were reviewed.

Results: The median age of the 74 eligible patients was 59 years. An Eastern Cooperative Oncology Group performance status 3–4 was present in 53 patients (73%), and 52 patients (70%) had ovarian cancer. Paracentesis followed by TA administration was performed in 65 patients (88%), and 37 patients (50%) were treated in a palliative setting. Chemotherapy or surgery after TA administration was performed in 37 patients (50%) in an aggressive setting, of which 14 patients (19%) were treated at the primary phase and 23 patients (31%) were treated at recurrent phase. The time interval of serial drainage was prolonged in 15 of 19 assessable patients, resulting in a response rate of 79% (95% confidence interval [95% CI]: 54–94%). Median overall survival after TA therapy in a palliative setting was 36 days (95% CI: 19–58 days). After TA therapy in a palliative setting, one patient complained of mild abdominal pain, two patients with advanced peritonitis carcinomatosa experienced bowel perforation, and three patients died within 7 days owing to disease progression.

Conclusions: Intraperitoneal and intrapleural TA administration were feasible and effective in symptomatic control of ascites and pleural effusion.

KEY WORDS: Ascites, intraperitoneal therapy, intrapleural therapy, pleural effusion, triamcinolone acetonide

INTRODUCTION

The majority of patients with advanced or recurrent ovarian cancer suffer from malignant ascites, resulting in frequent complaints of abdominal distension owing to massive ascites; frequent paracentesis is often needed for symptom relief.^[1-3] Massive ascites can be observed at the first visit, and prompt management of ascites is also required before primary surgery or chemotherapy. Management includes diuretics and salt restriction, concentrated ascites reinfusion therapy, and the

implantation of peritoneovenous shunts.^[4] Recently, catumaxomab, a trifunctional antibody against epithelial cell-adhesion molecules and CD3, was approved in Europe.^[5]

Malignant pleural effusion is also a cause of distress in patients with ovarian cancer. Symptom control

This is an open access article distributed under the terms of the Creative Commons Attribution-NonCommercial-ShareAlike 3.0 License, which allows others to remix, tweak, and build upon the work non-commercially, as long as the author is credited and the new creations are licensed under the identical terms.

For reprints contact: reprints@medknow.com

Cite this article as: Ito K, Tsubamoto H, Inoue K, Miyoshi Y, Ito Y, Hori K. Effectiveness of intraperitoneal or intrapleural administration of triamcinolone acetonide for the control of malignant ascites and pleural effusion (Kansai Clinical Oncology Group-G1102 study). *J Can Res Ther* 2017;13:446-50.

Kimihiko Ito, Hiroshi Tsubamoto¹, Kayo Inoue¹, Yukari Miyoshi², Yoshihiro Ito¹, Kensuke Hori

Department of Obstetrics and Gynecology, Kansai Rosai Hospital, Amagasaki, ¹Department of Obstetrics and Gynecology, Hyogo College of Medicine, Nishinomiya, Hyogo, ²Department of Obstetrics and Gynecology, Minoh City Hospital, Minoh, Osaka, Japan

For correspondence:

Dr. Kimihiko Ito, Department of Obstetrics and Gynecology, Kansai Rosai Hospital, 3-1-69 Inabaso, Amagasaki, Hyogo 660-8511, Japan. E-mail: kimihiko-ito@kanrou.net

Access this article online

Website: www.cancerjournal.net

DOI: 10.4103/0973-1482.176426

Quick Response Code:



in terminally ill patients primarily involves thoracentesis and pleurodesis.^[6] Talc has also been shown to be effective and a low-cost option for chemical pleurodesis, but yields pain and fever.^[7]

Malignant ascites and pleural effusion were sometimes detected and troubled the patients with endometrial or cervical cancer as well as ovarian, primary peritoneal, or fallopian tube cancer.

Both triamcinolone hexacetonide (TH) and triamcinolone acetonide (TA) are frequently used for the treatment of rheumatoid arthritis and juvenile rheumatoid arthritis, and reduction of inflammatory pain is more effective with intra-articular triamcinolone than with betamethasone and methylprednisolone,^[8] although TH was reported to be more effective than TA. Mackey *et al.* reported the usefulness of intraperitoneal administration of TH for symptomatic malignant ascites.^[9] Because TH has not been available in Japan; TA, which is slowly metabolized similar to corticosteroids and is inexpensive, has been administered to patients with malignant effusion following paracentesis or thoracentesis since 2005, after the approval of the Local Ethics Committees at each center.

This multicenter retrospective study was conducted to evaluate the efficacy of and toxicity associated with TA for the control of malignant ascites and/or pleural effusion.

MATERIALS AND METHODS

We conducted a retrospective review of the medical records of patients who were intraperitoneally or intrapleurally administered 400 mg TA following paracentesis or thoracentesis at our hospitals between 2005 and 2014. Patients were included if they had histologically confirmed gynecological cancer and cytologically determined malignant ascites or pleural effusion. This study was approved by the Kansai Clinical Oncology Group and each institutional review board and was carried out according to the Helsinki Declaration. Owing to the retrospective nature of the chart review, written informed consent was not obtained from all study participants. However, the study design was provided on the website of each institution to provide an opportunity to decline study participation.

TA was administered for patients around the time of surgery or chemotherapy as part of aggressive treatment or as part of best supportive care for patients in the palliative setting.

The treatment protocol included ultrasound examination for localization of ascites or pleural effusion followed by local anesthesia, and a 12–18-gauge needle or catheter was used for spontaneous drainage. Paracentesis was continued until flow ended, and thoracentesis was ended when a maximum of 1000 mL was drained. Then, patients received 400 mg (40 mL)

of TA by intraperitoneal or intrapleural bolus injection. After paracentesis, patients were instructed to change position every 5 min over a 30-min period to distribute the agent throughout the peritoneal space. All patients were monitored for 1 night in the hospital.

Patients were instructed to contact the physician when they experienced symptoms. The treatment protocol was repeated until the drainage frequency decreased. The efficacy was determined by comparing the time intervals of serial drainage before and after the first TA administration. TA administration was considered effective if the time interval of drainage increased after the treatment. In patients, who underwent surgery or chemotherapy before the next paracentesis or thoracentesis after TA administration, we compared the difference between the prior drainage interval and the interval from the TA administration to the surgery or chemotherapy. Patients who had surgery or chemotherapy before TA administration and who had TA administration following the first paracentesis or thoracentesis were excluded from the assessment of efficacy. The assessment of toxicity after TA administration was conducted using the National Cancer Institute Common Toxicity Criteria (NCI CTC) version 4.0 for all patients.

Exploratory analyses of efficacy and safety were prespecified for the subgroup of patients with ascites or pleural effusion. Overall survival (OS) was defined as the time from the 1st day of intraperitoneal or intrapleural TA administration to death by any cause in the cases in the palliative setting. Survival curves were estimated using the Kaplan–Meier method. Statistical analysis was conducted using XLSTAT 2014 (Addinsoft, Paris, France). Statistical significance was determined at $P < 0.05$.

RESULTS

Patient characteristics

Between 2005 and 2014, 74 women were eligible for inclusion [Table 1]. Their median age was 59 years (range: 36–81). Paracentesis and thoracentesis with TA administration were performed in 65 (88%) and 9 (12%) patients, respectively. Chemotherapy or surgery after TA was not performed in 37 (50%) patients, who were designated as palliative. The remaining 37 (50%) patients were considered to receive aggressive therapy; they underwent paracentesis or thoracentesis followed by TA administration scheduled around chemotherapy or surgery. Eastern Cooperative Oncology Group (ECOG) performance status (PS) 3 was present in 19 patients, and two patients had an ECOG PS 4 and underwent chemotherapy after TA administration.

Hepatitis B surface antigen was negative in all patients. No patient had a history or active infection of tuberculosis. One patient had diabetes. Medications included oral steroids ($n = 10$), intravenous steroids ($n = 3$), oral medroxyprogesterone acetate ($n = 4$), and diuretics ($n = 21$).

Table 1: Characteristics of patients with gynecologic cancer and malignant ascites or pleural effusion (n=74)

	n (%)
ECOG PS	
1	3 (4)
2	17 (23)
3	46 (62)
4	8 (11)
Primary disease	
Ovarian cancer	52 (70)
Primary peritoneal cancer	9 (12)
Fallopian tube cancer	1 (1)
Endometrial cancer	7 (10)
Cervical cancer	5 (7)
Stage at TA administration	
Primary	23 (31)
Recurrence	51 (69)
Site of TA administration	
Peritoneal cavity	65 (88)
Pleural cavity	9 (12)
Palliative setting	37 (50)
Aggressive setting	37 (50)
Primary phase	
Before the initial CT or surgery	7 (10)
<30 days after initial CT or surgery	4 (5)
Progression during initial therapy	3 (4)
Recurrent phase	
Before the secondary CT	17 (23)
<30 days after secondary CT	2 (3)
Progression during secondary CT	4 (5)
Number of TA administration	
1	56 (75)
2	13 (18)
≥3	5 (7)

ECOG=Eastern Cooperative Oncology Group, PS=Performance status, TA=Triamcinolone acetonide, CT=Chemotherapy

No patient had been treated with either intraperitoneal and intrapleural TA administration.

Efficacy

After drainage and TA therapy, ECOG PS improved in 67 of the 74 (87%) patients. The time interval between serial drainage before and after TA administration was assessable in 19 patients, and the median interval was 4 days (range: 5–18 days). Prolonged intervals were observed in 13 of 16 patients after paracentesis and two of three patients after thoracocentesis. The response rate was considered to be 79% (95% confidence interval [95% CI], 54–94%) [Figure 1].

Of the 37 patients in the palliative setting, the median OS was 36 days (95% CI: 19–58 days), with four patients censored who were transferred to hospice and not followed [Figure 2]. The subset analysis of OS between patients with paracentesis and thoracocentesis revealed no significant difference ($P = 0.98$). One patient with primary peritoneal cancer who had frequent thoracocentesis followed by TA administration in the palliative setting survived for 547 days after the initial TA therapy.

Toxicity

One patient with ovarian cancer of International Federation of Gynecology and Obstetrics stage IIIC had paracentesis before and during the first cycle of the initial chemotherapy. She

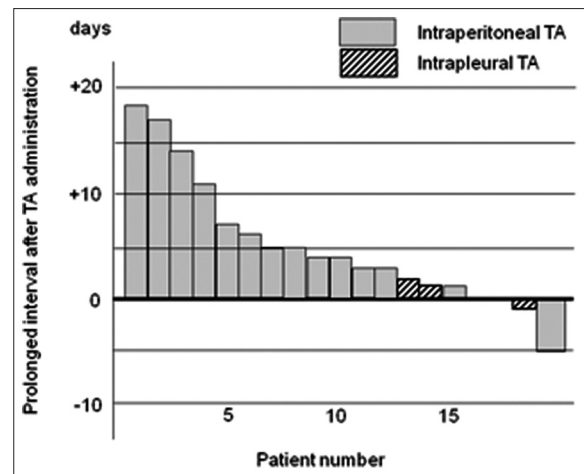


Figure 1: Response to triamcinolone acetonide (n = 19), based on the difference in the intervals between paracentesis or thoracocentesis, compared before and after triamcinolone acetonide administration

complained of abdominal pain (NCI CTC version 4 grade 2) a day after the second paracentesis followed by TA therapy. Two patients with advanced peritonitis carcinomatosis experienced bowel perforation 6 and 8 days after TA therapy in the palliative setting. One was treated with conservative management and died 20 days later, while the other underwent emergent surgery and survived for 169 days. Three patients in the palliative setting died within 7 days after TA administration, possibly owing to disease progression.

DISCUSSION

Of the various cancer types, ovarian cancer frequently results in symptomatic malignant ascites throughout the disease course.^[10] Vascular and/or lymph node metastasis likely blocks fluid reabsorption, resulting in intraperitoneal or intrapleural retention of malignant fluid. In addition, molecular crosstalk between the tumor and surrounding cells leads to local over-expression of various growth factors, of which vascular endothelial growth factor (VEGF) is a key molecule that elevates capillary permeability.^[11,12]

A Phase III clinical trial of bevacizumab, which is the monoclonal antibody of VEGF, in platinum-resistant ovarian cancer demonstrated a substantial reduction in the frequency of paracentesis in addition to improved quality of life (QOL).^[13,14] In Phase II studies of nonsmall cell lung cancer, the addition of bevacizumab was effective in patients with malignant pleural effusion.^[15,16] Aflibercept, which binds VEGF-A, B, and placental growth factor, has also shown efficacy in the treatment of malignant ascites in ovarian cancer.^[17,18] Furthermore, Mackey *et al.* postulated that the control of ascites by intraperitoneal TH administration is mediated by a reduction in VEGF secretion.^[9] In 15 patients with recurrent cancer, the interval between paracentesis increased from a mean of 9.5 ± 1.6 days to 17.5 ± 2.7 days, and the median OS was 42 days.^[9] Although the increase in

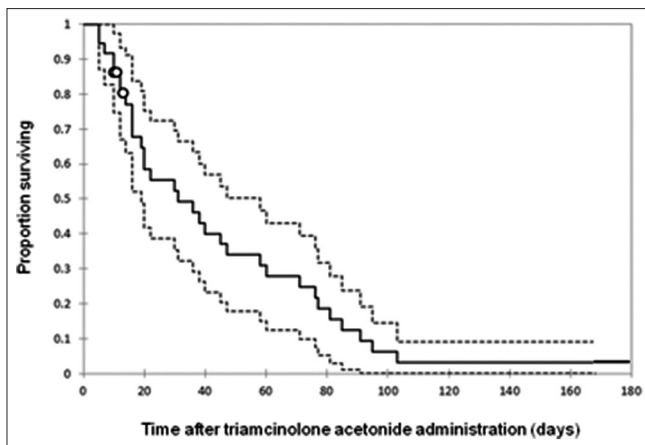


Figure 2: Kaplan–Meier analysis of overall survival after triamcinolone acetonide administration in the palliative setting in patients with gynecologic cancer ($n = 37$). Dashed lines indicate the upper and lower limit of the 95% confidence interval of the survival curve. Median overall survival was 36 days (95% confidence interval: 19–58 days)

the interval duration between paracentesis was longer than that of the current study, OS was similar.

Salvage intraperitoneal or intrapleural chemotherapy has been used in daily practice with the aim of prompt management with less toxicity. Chemotherapy for ovarian cancer has included platinum and taxane since the 1990s, and the current standard first-line regimen is combination paclitaxel and carboplatin. However, refractory disease is reported to be resistant to both platinum and taxane, even with high intraperitoneal concentrations.^[19,20]

The median OS after TA therapy in the palliative setting in this study was 36 days (95% CI: 19–58 days). Considering that the median OS in late stage ovarian cancer after the final chemotherapy was 68 days at the teaching hospital of Hyogo College of Medicine,^[21] TA therapy was unlikely to be associated with a survival benefit in patients with malignant effusion. However, in randomized trials of targeted therapy that included catumaxomab and bevacizumab, reduction in effusion and improved QOL did not lead to improved survival.^[5,13,14]

This study is the first report to describe intrapleural TA administration following thoracocentesis. Although there were only three assessable patients, intrapleural administration in the palliative setting appeared to be clinically effective in 2 of 6 nonassessable patients. One patient with recurrent cervical cancer and PS 4 did not appear suitable for chemical talc pleurodesis, and she could not be discharged because of frequent thoracocentesis. After two consecutive TA administrations, the drainage interval increased by 10 days. She could stay at home for several days with her family, and she died 39 days after the second intrapleural TA administration. Another patient with recurrent primary peritoneal cancer received 21 intrapleural TA administrations, and she remained

alive for 547 days without chemotherapy or other aggressive treatment.

Our study had several limitations. It was a retrospective study with a small sample size. Because adverse events were reviewed from the medical chart, only severe complications might have been described. We observed two cases of bowel perforation. Both cases were ovarian cancer patient with advanced peritonitis carcinomatosis and massive ascites. A case was a 61-year-old woman. At first, we performed probe laparotomy, but we could not resect the tumor because her all organ in abdominal cavity firmly adhered together by carcinomatosis. She was treated paracentesis followed by TA administration 4 days later of the probe laparotomy. Her PS was improved from 4 to 3. However, she progressed to ileus, and we observed small free air in abdominal cavity by computed tomography examination 7 days later of the TA administration. We considered bowel perforation but treated palliative because her general condition was poor. She died 20 days after TA administration. In this case, the relationship between TA administration and bowel perforation was unclear. Another case was a 55-year-old woman. She was treated paracentesis followed by TA administration and discharged next day. Her PS was improved from 2 to 1. Four days later, she complained sudden abdominal pain and was admitted emergency. We diagnosed pan-peritonitis from bowel perforation and performed an emergent laparotomy. We observed perforation of ileum that diameter was 1 cm, and performed partial ileostomy and creation of a stoma. The all layer of ileum around the perforation was histologically invaded by adenocarcinoma. We considered that the bowel perforation was not directly caused by TA administration in this case. She recovered to PS 1 and discharged 33 days after the emergent surgery. She died 169 days after TA administration. However, she was never need paracentesis after emergency surgery. Nevertheless, the results of this study indicate that a novel procedure using a common, low-cost steroid rapidly improved malignant symptomatic effusion with acceptable toxicity; these results could serve as a pilot study for future large, multicenter, prospective studies.

Financial support and sponsorship

Nil.

Conflicts of interest

There are no conflicts of interest.

REFERENCES

1. Kipps E, Tan DS, Kaye SB. Meeting the challenge of ascites in ovarian cancer: New avenues for therapy and research. *Nat Rev Cancer* 2013;13:273-82.
2. Malayev Y, Levene R, Gonzalez F. Palliative chemotherapy for malignant ascites secondary to ovarian cancer. *Am J Hosp Palliat Care* 2012;29:515-21.

Ito, *et al.*: The control of malignant ascites and pleural effusion

3. Eskander RN, Tewari KS. Emerging treatment options for management of malignant ascites in patients with ovarian cancer. *Int J Womens Health* 2012;4:395-404.
4. Japanese CART Study Group, Matsusaki K, Ohta K, Yoshizawa A, Gyoda Y. Novel cell-free and concentrated ascites reinfusion therapy (KM-CART) for refractory ascites associated with cancerous peritonitis: Its effect and future perspectives. *Int J Clin Oncol* 2011;16:395-400.
5. Heiss MM, Murawa P, Koralewski P, Kutarska E, Kolesnik OO, Ivanchenko VV, *et al.* The trifunctional antibody catumaxomab for the treatment of malignant ascites due to epithelial cancer: Results of a prospective randomized phase II/III trial. *Int J Cancer* 2010;127:2209-21.
6. Bradshaw M, Mansfield A, Peikert T. The role of vascular endothelial growth factor in the pathogenesis, diagnosis and treatment of malignant pleural effusion. *Curr Oncol Rep* 2013;15:207-16.
7. Ried M, Hofmann HS. The treatment of pleural carcinosis with malignant pleural effusion. *Dtsch Arztebl Int* 2013;110:313-8.
8. Garg N, Perry L, Deodhar A. Intra-articular and soft tissue injections, a systematic review of relative efficacy of various corticosteroids. *Clin Rheumatol* 2014;33:1695-706.
9. Mackey JR, Wood L, Nabholtz J, Jensen J, Venner P. A phase II trial of triamcinolone hexacetonide for symptomatic recurrent malignant ascites. *J Pain Symptom Manage* 2000;19:193-9.
10. Ayantunde AA, Parsons SL. Pattern and prognostic factors in patients with malignant ascites: A retrospective study. *Ann Oncol* 2007;18:945-9.
11. Dvorak HF, Nagy JA, Feng D, Brown LF, Dvorak AM. Vascular permeability factor/vascular endothelial growth factor and the significance of microvascular hyperpermeability in angiogenesis. *Curr Top Microbiol Immunol* 1999;237:97-132.
12. Dvorak HF. Vascular permeability factor/vascular endothelial growth factor: A critical cytokine in tumor angiogenesis and a potential target for diagnosis and therapy. *J Clin Oncol* 2002;20:4368-80.
13. Pujade-Lauraine E, Hilpert F, Weber B, Reuss A, Poveda A, Kristensen G, *et al.* Bevacizumab combined with chemotherapy for platinum-resistant recurrent ovarian cancer: The AURELIA open-label randomized phase III trial. *J Clin Oncol* 2014;32:1302-8.
14. Stockler MR, Hilpert F, Friedlander M, King MT, Wenzel L, Lee CK, *et al.* Patient-reported outcome results from the open-label phase III AURELIA trial evaluating bevacizumab-containing therapy for platinum-resistant ovarian cancer. *J Clin Oncol* 2014;32:1309-16.
15. Tamiya M, Tamiya A, Yamadori T, Nakao K, Asami K, Yasue T, *et al.* Phase 2 study of bevacizumab with carboplatin-paclitaxel for non-small cell lung cancer with malignant pleural effusion. *Med Oncol* 2013;30:676.
16. Kitamura K, Kubota K, Ando M, Takahashi S, Nishijima N, Sugano T, *et al.* Bevacizumab plus chemotherapy for advanced non-squamous non-small-cell lung cancer with malignant pleural effusion. *Cancer Chemother Pharmacol* 2013;71:457-61.
17. Gotlieb WH, Amant F, Advani S, Goswami C, Hirte H, Provencher D, *et al.* Intravenous aflibercept for treatment of recurrent symptomatic malignant ascites in patients with advanced ovarian cancer: A phase 2, randomised, double-blind, placebo-controlled study. *Lancet Oncol* 2012;13:154-62.
18. Colombo N, Mangili G, Mammoliti S, Kalling M, Tholander B, Sternas L, *et al.* A phase II study of aflibercept in patients with advanced epithelial ovarian cancer and symptomatic malignant ascites. *Gynecol Oncol* 2012;125:42-7.
19. Markman M. Second-line chemotherapy for refractory cancer: Intraperitoneal chemotherapy. *Semin Surg Oncol* 1994;10:299-304.
20. Tsubamoto H, Takeuchi S, Ito K, Miyagi Y, Toyoda S, Inoue K, *et al.* Feasibility and efficacy of intraperitoneal docetaxel administration as salvage chemotherapy for malignant gynaecological ascites. *J Obstet Gynaecol* 2015;35:69-73.
21. Tsubamoto H, Ito Y, Kanazawa R, Wada R, Hosoda Y, Honda O, *et al.* Benefit of palliative chemotherapy and hospice enrollment in late-stage ovarian cancer patients. *J Obstet Gynaecol Res* 2014;40:1399-406.